



Immunohistochemical Study of Cyclooxygenase-2 Expression in Prostate Carcinoma; It's Relation with Apoptosis and Angiogenesis

İmmünohistokimyasal Çalışma ile Prostat Karsinomunda Siklooksijenaz-2 Ekspresyonunun; Apoptozis ve Anjiyogenezis ile İlişkisi

Emine Kılıç Bağır MD¹, Arbil Açıklalın MD¹, Volkan İzol MD², Gülşah Şeydaoğlu MD³, Şeyda Erdoğan MD¹

¹Çukurova University Faculty of Medicine, Department of Pathology, Adana, Turkey

²Çukurova University Faculty of Medicine, Department of Urology, Adana, Turkey

³Çukurova University Faculty of Medicine, Department of Biostatistics, Adana, Turkey

Summary

Objective: Prostate carcinoma (PC) is one of the most commonly diagnosed cancer types with significant rates of mortality and morbidity. The etiology of PC is not clear. Cytokine and mediators at the inflammatory pathway plays role at the various steps of the relation between chronic inflammation and cancer. The objective of this study is to determine if there is relationship between cyclooxygenase-2 (COX) apoptosis and angiogenesis in patients with PC.

Materials and Methods: Sample of 49 cases who were at pathologic stage pT2 and underwent radical prostatectomy, were selected retrospectively between 2005-2010, from the archives of Pathology Department of Çukurova University Faculty of Medicine. Histologic slides of each case were reviewed for the diagnostic reassessment and graded by the Gleason scoring system. COX-2, vascular endothelial growth factor (VEGF), monoclonal antibody (M30) and bcl-2 were immunohistochemically applied to the cases and they were evaluated.

Results: The mean age of the patients were 63.8. Twenty-one cases had their Gleason score ≤ 6 and 28 had their Gleason score ≥ 7 . COX-2 expression was detected in 81.6% of cases. While COX-2 expression was significantly correlated with bcl-2 expression, there was no correlation between VEGF and COX-2 expression. Gleason score was negatively correlated with M30. It was detected that as COX-2 expression increased mean survival time significantly decreased.

Conclusion: This study makes us think that in the PC carcinogenesis COX-2 inhibits apoptosis rather than promoting angiogenesis. These results may offer new insights for the treatment strategies, also they may be useful for the prediction of clinical outcomes.

Keywords: Prostate carcinoma, COX-2, apoptosis, angiogenesis

Öz

Amaç: Prostat karsinomu (PK) önemli oranda ölümcül ve morbiditesi olan, sık görülen kanser türlerinden biridir. PK'nin etiyolojisi net değildir. Enflamatuvar yolaktaki sitokin ve mediatörler; kronik enflamasyon ve kanser arasındaki ilişkide, çeşitli basamaklarda rol oynamaktadır. Bu çalışmanın amacı, PK'li hastalarda siklooksijenaz-2 (COX), apoptozis ve anjiyogenezis arasında ilişki olup olmadığını belirlemektir.

Gereç ve Yöntem: 2005-2010 yılları arasında, patolojik evresi pT2 olup radikal prostatektomi uygulanan 49 olgu, Çukurova Üniversitesi Tıp Fakültesi Patoloji arşivinden retrospektif olarak seçilmiştir. Histolojik slaytlar tanısıl açıdan tekrar gözden geçirilmiş ve Gleason skorlama sistemine göre derecelendirilmiştir. Olgulara immünohistokimyasal olarak COX-2, vasküler endotelial büyüme faktörü (VEGF), monoklonal antikor (M30), bcl-2 uygulanarak değerlendirilmiştir.

Bulgular: Hastaların ortalama yaşı 63,8 idi. Yirmi bir hasta Gleason skor ≤ 6 ve 28 hasta Gleason skor ≥ 7 olarak derecelendirildi. COX-2 ekspresyonu %81,6 hastada tespit edildi. COX-2 ekspresyonu bcl-2 ekspresyonu ile korele olarak bulunurken, VEGF ile COX-2 arasında korelasyon saptanmadı. Gleason skor ile M30 arasında negatif korelasyon saptandı. Ortalama yaşam ve COX-2 arasında negatif korelasyon saptandı. COX-2 ekspresyonu arttıkça sağkalım süresinin anlamlı olarak azaldığı saptandı.

Sonuç: Çalışmamız PK karsinogenezisinde COX-2'nin anjiyogenezisi arttırmaktan çok apoptozisi inhibe ederek etki ettiğini düşündürmektedir. Bu sonuçların, tedavi stratejilerine yeni bakış açıları sunabileceği gibi, hastaların klinik takiplerinin sonuçlarını öngörmede faydalı olabileceğini düşünmekteyiz.

Anahtar Kelimeler: Prostat karsinomu, COX-2, apoptozis, anjiyogenezis

Introduction

Cyclooxygenase (COX) is the enzyme that responsible for the production of prostaglandins from arachidonic acid. A number of studies suggest an important role of COX-2 in pathophysiology of inflammation and carcinogenesis. It plays role in tumorigenesis of several human malignancies. It's reported that COX-2 stimulates cell proliferation, inhibits epithelial differentiation and apoptosis, mediates immune suppression and increases the production of mutagens (1,2,3,4,5).

Apoptosis is one the most important event at the pathogenesis of varies diseases including neoplastic process. There are several immunohistochemical methods for demonstrating apoptosis at the cells. Among these terminal deoxynucleotidyl transferase dUTP nick end labeling (TUNEL) method is the most common method. On the other hand monoclonal antibody (M30) is the alternative method for detecting early stage of apoptosis that is specific for epithelial cells (Sharma) (6).

The objective of this study is to determine if there is relationship between COX-2, apoptosis and angiogenesis in prostate carcinomas (PC).

Materials and Methods

Samples from 49 cases who are at pathologic stage pT2 and undergoing radical prostatectomy, were selected retrospectively between 2005-2010, from the archives of Pathology Department of Çukurova University, Medical Faculty. Histologic slides of each case were reviewed for the diagnostic reassessment and graded by the Gleason scoring system. The excluding criterias were different stages, metastasis and lost follow-up. Approval of the Ethics Committee obtained for the study (Approval date: 21.09.2016; Decision No: 50243401/2016-11).

Immunohistochemical staining was performed on 5-mm sections of formalin-fixed, paraffin-embedded tissue using antibody COX-2 (1/50, Santa Cruz), vascular endothelial growth factor (VEGF) A (1/80, Santa Cruz), M30 (1/50, Roche), bcl-2 (1/50, DAKO). The visualization system used was BenchMark XT with heat-induced epitope retrieval (CC1 solution) and iView DAB detection kit (Ventana, Tucson, AZ). Cytoplasmic and

membranous staining was considered positive for COX-2, VEGF and bcl-2. Nuclear staining was accepted as positive for M30.

Statistical Analysis

For each continuous variable, normality was checked. Since the data was not distributed normally, appropriate non-parametric test was chosen. Correlations between the variables were tested by Spearman or Pearson's correlation test. The correlation coefficients were interpreted as either excellent relationship $r \geq 0.91$; good $0.90 \leq r \leq 0.71$; moderate- fair $0.70 \leq r \leq 0.51$; weak $0.50 \leq r \leq 0.31$; little or none $r \leq 0.3$. The rates of mean or median survival were estimated with the use of the Kaplan-Meier method and the curves were compared with the use of the log-rank test. A p value of 0.05 was taken as the level of significance. SPSS ver 22.0 were used for analyses.

Immunohistochemical Evaluation

The results of staining for COX-2, bcl-2 and VEGF were analyzed semiquantitatively by using an immunohistochemical scoring (IHS) system that combines the percentage of immunoreactive cells (quantity score) and an estimate of staining intensity (staining intensity score). Staining quantity was scored by using a modified version of the method described by Kelly et al. (1): no staining is 0, 1-10% of cells stained are scored as 1, 11-50% as 2, 51-80% as 3 and 81-100% as 4. Staining intensity was scored on a scale of 0-3 where 0 is no staining, 1 is weak, 2 is moderate and 3 is strong. The staining intensity score and staining quantity score were multiplied to give the IHS. An IHS of 9-12 was considered strong immunoreactivity; 5-8 moderate, 1-4 weak and 0 was considered as negative.

Apoptosis was figured out by monoclonal antibody M30, which reacts with the product from the cleavage of cytokeratin 18 (CK18). The number of M-30 positive cells per 1000 cells was expressed as apoptotic index (Figure 1).

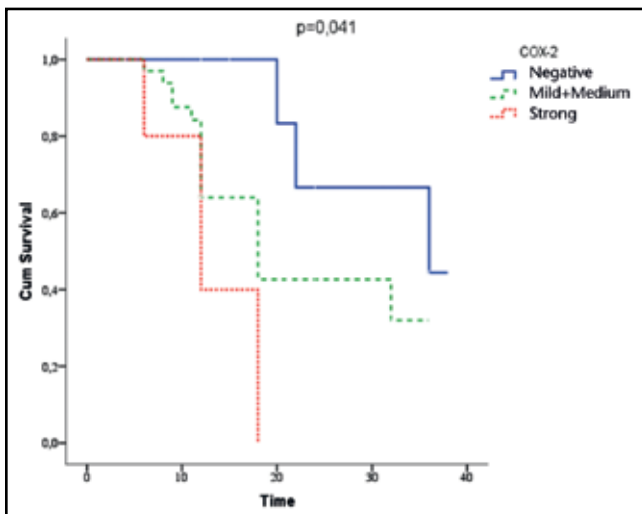


Figure 2. Survival curves according to Cyclooxygenase-2 expression

COX: Cyclooxygenase

Table 1. Correlation between Cyclooxygenase-2, monoclonal antibody and other parameters

	COX-2 r p	M30 r p
Grade	0.177	-0.28
	0.223	0.048
AGE	0.346	-0.021
	0.066	0.912
bcl-2	0.490	-0.198
	0.000	0.173
VEGF	-0.010	0.127
	0.945	0.385
M30	-0.091	
	0.534	-

COX: Cyclooxygenase, M30: Monoclonal antibody, VEGF: Vascular endothelial growth factor, r= Correlation coefficient

Results

The age of the patients ranged from 48 to 73 years old (average 63.8 ± 6.4). Twenty-one (42.8%) of the cases had Gleason score ≤ 6 and 28 (57.2%) had Gleason score ≥ 7 . COX-2 expression was detected in 81.6% of cases. However there was no correlation between COX-2 and M30 and VEGF expression ($p > 0.05$) there was a positive moderate correlation between COX-2 with bcl-2 expression ($r = 0.49$; $p < 0.0001$) (Table 1). No significant relation was found between Gleason score and COX-2, VEGF and bcl-2. There was a negative weak correlation between Gleason score and M30 ($r = -0.28$; $p = 0.04$).

Negative correlation between COX-2 expression and mean survival was also observed ($p = 0.041$) (Figure 2). The mean survival time was 31.8 months for the patients with no COX-2 expression, 22.5 months for the patients with low and moderate COX-2 and 13.2 months for the strong COX-2 ($p = 0.041$).

Discussion

COX-2 is a stimulated enzyme that transforms arachidonic acid to prostaglandins, which are strong mediators of inflammation. Several studies showed that COX-2 plays a key role in tumorigenesis at the various malignancies by inducing cell proliferation, metastasis, inhibiting epithelial differentiation and apoptosis and mediating factors of immune suppression (2,3,4). COX-2 expression in prostate tissues or PC has been the issue of many recent studies. COX-2 expression also have examined in inflammatory process such as post-atrophic hyperplasia, prostate intraepithelial neoplasia, and PC (5,6,7). But way of their effect is unclear and controversial. Zha et al. (8) found negative COX-2 at 144 samples of PC in their study. On the

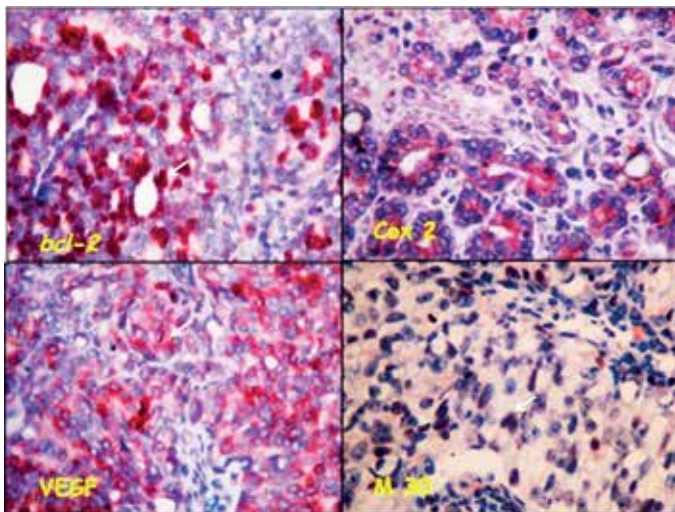


Figure 1. Immunohistochemical staining of Cyclooxygenase-2, vascular endothelial growth factor, monoclonal antibody, bcl-2 in human prostat carcinoma tissue samples. Bcl-2, COX 2 and vascular endothelial growth factor intracytoplasmic expression and positive staining in tumor cells monoclonal antibody nuclear positivity in tumor cells (white arrow sign positive tumor cells)

COX: Cyclooxygenase, M30: Monoclonal antibody, VEGF: Vascular endothelial growth factor

other hand, there are some reports that COX-2 expression has been analyzed in non-neoplastic prostate tissue such as post-atrophic hyperplasia or proliferative inflammatory atrophy (8,9). Additionally, a great majority of the studies have identified overexpression of COX-2 in PC and prostate intraepithelial neoplasia (3,10).

Several types of human malignancies overexpress COX-2 along with VEGF (2,10,11,12). Increased expression of angiogenic factors, and decreased expression of anti-angiogenic factors, or a combination of both events is the result of cancer induced angiogenesis (9,13). COX-2 was expressed in newly formed blood vessels within tumors (14). VEGF is the most important tumor angiogenic factors that cause the proliferation of vascular endothelial cells. In the literature, there are some controversial studies about the COX-2 and angiogenesis at the PC. Wang et al. (15) reported a direct link between COX-2 and angiogenesis. Also Kim et al. (3) showed a significant correlation between the overexpression of COX-2 and VEGF that was associated with inflammation and carcinoma. However Mukherjee et al. (4) couldn't find significant correlation between COX-2 and angiogenesis in PC's. Also we couldn't find statistically significant correlation between COX-2 and VEGF.

An epitope, situated on CK18, becomes exposed at an early caspase cleavage event during apoptosis, and is not seen in viable epithelial cells. A novel M30 recognizes this neo-epitope on CK18 early in apoptosis. CK18 is divided by caspases at two different sites during apoptosis. This division pattern is special for apoptosis. It can be obtained using recombinant caspase-3 and caspase-6 to in vitro studies (16,17,18). Although various techniques such as TUNEL has been described, we used M30 to evaluate apoptotic index which was more simple and easy to perform (12). M30 is much more sensitive and specific for epithelial cells whereas TUNEL identifies all apoptotic cells in addition to epithelial lineage (19). Also M30 positivity comes out at an early stage of apoptosis and remains positive till to the necrosis of the tumor cells (15,18). For that reason, we thought that apoptosis exposed by M30 would be much more suitable for PC on the base of epithelial origin. Yin et al. (20) reported CK18 was downregulated in poorly differentiated PC tissue samples, indicating a potential association of the downregulation of CK18 with tumor aggressiveness. Our data demonstrated Gleason score was negatively correlated with M30. This result can be explained by localization of M30 on CK18 that cause this down regulation at higher Gleason scores. Bcl-2 is equilibrate between proapoptotic and antiapoptotic members which is a significant factor of tumorigenesis. Bcl-2 gene mutation in tumor cells, results with the increased expression and suppression of the proapoptotic proteins. Proapoptotic protein gene mutation causes a down-regulation of expression, and the cell loses ability of regulation apoptosis-again tumorigenesis (3,11). Kim et al. (3) reported meaningful correlation between the COX-2 and bcl-2 overexpression that their progressive overexpression was dependent to chronic inflammation and carcinoma. On the other hand Tanji et al. (11) found positive, but not significant correlation between bcl-2 and COX-2 expression. In our study bcl-2 and COX-2 was positively correlated.

We found an overexpression of COX-2 in PC. Unlike some reports, we found no relationship between COX-2 and angiogenesis. However, COX-2 was significantly positive correlated with bcl-2. Our results raise the possibility that COX-2 may influence tumor progression in PC through inhibiting apoptosis rather than the promotion of angiogenesis. The use of selective agents targeting apoptosis and COX-2 may play role in the treatment of PC.

Our results of survival analysis showed that expression of COX-2 is associated with a significantly worse survival. In this regard, overexpression of COX-2 may be useful for assessing the biologic behaviour of PC.

We acknowledge this study has some limitations such as small number of cases lack of using molecular technics to detect apoptosis and angiogenesis. In summary, our results must be supported by further studies to offer new insights into the treatment strategies and to predict clinical outcome.

Ethics

Ethics Committee Approval: Date: 21.09.2016; Decision No: 50243401/2016-11, Informed Consent: It was taken.

Peer-review: Internal peer-reviewed.

Authorship Contributions

Concept: Emine Kılıç Bağır, Arbil Açıkalın, Volkan İzol, Gülşah Şeydaoğlu, Şeyda Erdoğan, Design: Emine Kılıç Bağır, Arbil Açıkalın, Volkan İzol, Gülşah Şeydaoğlu, Şeyda Erdoğan, Data Collection or Processing: Arbil Açıkalın, Volkan İzol, Analysis or Interpretation: Arbil Açıkalın, Literature Search: Gülşah Şeydaoğlu, Şeyda Erdoğan, Writing: Emine Kılıç Bağır, Şeyda Erdoğan.

Conflict of Interest: No conflict of interest was declared by the authors.

Financial Disclosure: The authors declared that this study received no financial support.

References

1. Kelly LM, Hill AD, Kennedy S, et al. Lack of prognostic effect of Cox-2 expression in primary breast cancer on short-term follow-up. *Eur J Surg Oncol* 2003; 29:707-710.
2. Fosslien E. Review: Molecular pathology of cyclooxygenase-2 in cancer induced angiogenesis. *Ann Clin Lab Sci* 2001; 31:325-348.
3. Kim BH, Kim CI, Chang HS, et al. Cyclooxygenase-2 overexpression in chronic inflammation associated with benign prostatic hyperplasia: is it related to apoptosis and angiogenesis of prostate cancer? *Korean J Urol* 2011; 52:253-259.
4. Mukherjee R, Edwards J, Underwood MA, et al. The relationship between angiogenesis and cyclooxygenase-2 expression in prostate cancer. *BJU Int* 2005; 96:62-66.
5. Kirschenbaum A, Klausner AP, Lee R, et al. Expression of cyclooxygenase-1 and cyclooxygenase-2 in the human prostate. *Urology* 2000; 56:671-676.
6. Madaan S, Abel PD, Chaudhary KS, et al. Cytoplasmic induction and over-expression of cyclooxygenase-2 in human prostate cancer: implications for prevention and treatment. *BJU Int* 2000; 86:736-741.
7. Yoshimura R, Sano H, Masuda C, et al. Expression of cyclooxygenase-2 in prostate carcinoma. *Cancer* 2000; 89:589-596.
8. Zha S, Gage WR, Sauvageot J, et al. Cyclooxygenase-2 is up-regulated in proliferative inflammatory atrophy of the prostate, but not in prostate carcinoma. *Cancer Res* 2001; 61:8617-8623.
9. Denkert C, Thoma A, Niesporek S, et al. Overexpression of cyclooxygenase-2 in human prostate carcinoma and prostatic intraepithelial neoplasia-association with increased expression of Polo-like kinase-1. *Prostate* 2007; 67:361-369.
10. Lee LM, Pan CC, Cheng CJ, et al. Expression of cyclooxygenase-2 in prostate adenocarcinoma and benign prostatic hyperplasia. *Anticancer Res* 2001; 21:1291-1294.
11. Tanji N, Kikugawa T, Yokoyama M. Immunohistochemical study of cyclooxygenases in prostatic adenocarcinoma; relationship to apoptosis and Bcl-2 protein expression. *Anticancer Res* 2000; 20:2313-2319.
12. Kusama K, Jiang Y, Toguchi M, et al. Use of the monoclonal antibody M30 for detecting HSG cell apoptosis. *Anticancer Res* 2000; 20:151-154.
13. Swami S, Krishnan AV, Moreno J, et al. Inhibition of prostaglandin synthesis and actions by genistein in human prostate cancer cells and by soy isoflavones in prostate cancer patients. *Int J Cancer* 2009; 124:2050-2059.
14. Masferrer JL, Leahy KM, Koki AT, et al. Antiangiogenic and antitumor activities of cyclooxygenase-2 inhibitors. *Cancer Res* 2000; 60:1306-1311.
15. Wang W, Bergh A, Damber JE. Cyclooxygenase-2 expression correlates with local chronic inflammation and tumor neovascularization in human prostate cancer. *Clin Cancer Res* 2005; 11:3250-3256.
16. Yilmaz Y. Systematic review: caspase-cleaved fragments of cytokeratin 18 - the promises and challenges of a biomarker for chronic liver disease. *Aliment Pharmacol Ther* 2009; 30:1103-1109.
17. Faber TJ, Japink D, Leers MP, et al. Activated macrophages containing tumor marker in colon carcinoma: immunohistochemical proof of a concept. *Tumour Biol* 2012; 33:435-441.
18. Lee KS, Chung JY, Jung YJ, et al. The significance of caspase-cleaved cytokeratin 18 in pleural effusion. *Tuberc Respir Dis (Seoul)* 2014; 76:15-22.
19. Todenhofer T, Hennenlotter J, Faber F, et al. Significance of apoptotic and non-apoptotic disseminated tumor cells in the bone marrow of patients with clinically localized prostate cancer. *Prostate* 2015; 75:637-645.
20. Yin B, Zhang M, Zeng Y, et al. Downregulation of cytokeratin 18 is associated with paclitaxel resistance and tumor aggressiveness in prostate cancer. *Int J Oncol* 2016; 48:1730-1736.